



ELSEVIER

ORIGINAL ARTICLE

Evaluation of the Instability Severity Index score in predicting failure following arthroscopic Bankart surgery in an active military population

Andrew G. Chan, MD, MPH^{a,*}, Kelly G. Kilcoyne, MD^a, Stephen Chan, MD^a, Jonathan F. Dickens, MD^{b,c}, Brian R. Waterman, MD^d

^aDepartment of Orthopaedic Surgery, William Beaumont Army Medical Center, El Paso, TX, USA

^bDepartment of Orthopaedic Surgery, Walter Reed National Military Medical Center, Bethesda, MD, USA

^cUniformed Services University of the Health Sciences, Bethesda, MD, USA

^dDepartment of Orthopaedic Surgery, Wake Forest University School of Medicine, Winston-Salem, NC, USA

Background: The Instability Severity Index (ISI) score is a preoperative risk stratification tool used to identify patients at heightened risk of recurrent anterior instability after an arthroscopic Bankart procedure. The primary objective of this study was to validate the utility of the ISI score in predicting failure of primary arthroscopic Bankart surgery in an active-duty military population.

Methods: A retrospective study was performed to compare all military service members undergoing primary arthroscopic Bankart repairs at a single military treatment facility between 2007 and 2014. The primary outcome of interest was surgical failure due to recurrent instability. The ISI framework was used to stratify each patient for recurrence, and multivariate analysis was performed to evaluate the composite ISI score and individual domains between patients with and patients without failed Bankart repairs.

Results: A total of 131 patients were identified, with a mean patient age of 26.8 years (range, 19–47 years), among whom 42 patients (32%) were identified as having a higher-demand military occupation. At a minimum 2-year follow-up, 34 patients (26%) sustained recurrent anterior shoulder instability. The mean ISI score of patients in the failed Bankart repair group was not statistically different than that of patients with a successful repair (3.41 vs 3.5, $P = .74$), and no individual ISI domains were identified as independent risk factors for subsequent surgical failure or revision stabilization.

Conclusion: Contrary to the findings of previous validation studies, the composite ISI score and its individual risk factors were not predictive of subsequent surgical failure after primary arthroscopic Bankart repair in an active military population.

Level of evidence: Basic Science Study; Validation of Classification System

Published by Elsevier Inc. on behalf of Journal of Shoulder and Elbow Surgery Board of Trustees.

Keywords: Shoulder; instability; dislocation; Bankart; ISI; Latarjet

This study was performed with approval from the Regional Health Command-Central Institutional Review Board (Fort Sam Houston, TX, USA), which oversees William Beaumont Army Medical Center (reference No. C.2017.063).

*Reprint requests: Andrew G. Chan, MD, MPH, Department of Orthopaedic Surgery, William Beaumont Army Medical Center, 5005 N Piedras St, El Paso, TX 79920, USA.

E-mail address: andrew.g.chan.mil@mail.mil (A.G. Chan).

Shoulder dislocations are a major health issue for the US military population. The shoulder joint is the most commonly dislocated joint because of its broad physiological range of motion, reliance on capsular and soft-tissue constraints, and poor osseous congruency.^{3,25,38} Young patient age, male

Table I Scoring of ISI score*

Prognostic factor	Score
Age at surgery	
≤20 yr	2
>20 yr	0
Glenoid loss of contour on AP radiograph	
Loss of contour	2
No loss of contour	0
Hill-Sachs lesion on external rotation AP radiograph	
Visible	2
Not visible	0
Degree of sports participation	
Competitive	2
Recreational or none	0
Type of sport	
Contact or forced overhead	1
Other	0
Shoulder hyperlaxity	
Present	1
Not present	0
Total possible score	10

ISI, Instability Severity Index; AP, anteroposterior.

* Rouleau et al²⁶ established an ISI score threshold of 4.8, Thomazeau et al³⁴ reported an ISI score of 4, and Phadnis et al²⁷ reported an ISI score threshold greater than 4 as a contraindication for an arthroscopic procedure.

sex, and involvement in at-risk activity are strong risk factors for sustaining recurrent anterior shoulder instability.^{25,40} The US military is a high-risk population for shoulder dislocations owing to its large proportion of young, male members and the physically demanding nature of the profession. A study on the epidemiology of shoulder dislocations in the US military from 1998–2006 revealed that the overall incidence was 7 times higher than that of the general US population.^{25,40}

Greater than 95% of shoulder dislocations are anterior.³⁸ Anterior shoulder instability is usually addressed surgically with either a modified Bristow-Latarjet coracoid transfer, open Bankart repair, or arthroscopic Bankart procedure. Studies demonstrate an instability recurrence rate of 26–100% following a first time dislocation event.²⁴ In recent years, there has been an increasing trend toward using arthroscopic stabilization for anterior shoulder instability, which has lower recurrence rates and favorable patient-reported outcomes.^{19,23,26,32} However, several studies have demonstrated significant rates of recurrent instability, ranging from 4% to 35%.^{23,35} Therefore, it is important to be able to identify the best surgical procedure to optimize patient-reported function and minimize the risk of secondary instability. The Instability Severity Index (ISI) score proposed by Balg and Boileau² identifies patients with preoperative characteristics that are associated with an unacceptably high risk of recurrent instability after primary arthroscopic Bankart procedures (Table I). Risk factors for recurrent instability include age younger than 20 years at the time of surgery, presence of glenoid bone loss before surgery, presence of a Hill-Sachs

lesion before surgery, type and level of athletic involvement, and objective evidence of shoulder hyperlaxity.^{2,3,23} The ISI score combines 6 preoperative risk factors and is scored from 1 to 10, with a score greater than 6 being associated with a 70% risk of recurrent dislocation after arthroscopic stabilization and being the traditional threshold for an open Latarjet procedure; in contrast, a score of 6 or less is associated with a 10% risk and yields a recommendation of arthroscopy.^{2,3,27,28} Subsequent studies have validated the ISI score as a useful risk assessment tool in an at-risk patient population and further advocated for preferential use of the Latarjet procedure over arthroscopic Bankart repair in patients with an ISI score of 3 or greater.^{2,27,28,34} However, this algorithm may be challenged in a military population that has significant risk factors for recurrent anterior shoulder instability. In the current model, many American surgeons still prefer arthroscopic stabilization as first-line treatment in the absence of glenohumeral bone loss. Therefore, the primary objective of this study was to evaluate the utility of the ISI score in predicting failure of primary arthroscopic Bankart surgery in an active US military population.

Methods

A retrospective case-control study was performed to compare all active-duty military service members by use of modern suture anchor-based surgical techniques with or without recurrent anterior shoulder instability after arthroscopic Bankart repair. All US military service members undergoing primary arthroscopic Bankart repair at a single military medical center between January 2007 and January 2014 were identified from the Department of Defense Military Surgical Scheduling System (S3, version 2.3). Any non-active-duty beneficiaries; patients with a concomitant rotator cuff or superior labral lesion, surgery for recurrent instability after previous anterior stabilization surgery, or combined posterior or multidirectional instability; individuals with less than 24 months' clinical follow-up; and/or cases of miscoding were excluded from the analysis. For the purposes of this study, failure was defined as anterior glenohumeral instability recurrence, including either a subluxation or dislocation event. Anterior shoulder dislocation was defined as a documented traumatic or atraumatic instability event requiring manual reduction by medical personnel, with or without confirmatory shoulder radiographs. Anterior subluxations were defined as transient instability events in which patients experienced provocative instability with spontaneous reduction.

Demographic parameters (age, sex, and military occupational specialty) and clinical variables were extracted. A retrospective review of the Department of Defense electronic medical record, Armed Forces Health Longitudinal Technology Application (AHLTA, version 3.3), was performed, and the ISI score was applied retrospectively to generate a composite score for each patient. Most patients also had advanced imaging such as magnetic resonance imaging, computed tomography (CT) arthrograms, or CT scans with 3-dimensional reconstruction, although these were not assessed as part of the preoperative risk stratification to replicate the criteria used in previous studies.²

The initial ISI score domains were adapted for the current military demographic. For the purposes of our study, sporting

participation was designated as “competitive” for all patients because of their routine involvement in organized unit athletic competition, physical fitness activities, and military training. All US military service members must adhere to well-defined baseline standards for physical fitness, such as those specified under Army Regulation 40-501 (Headquarters, Department of the Army, Washington, DC, USA), and generally require successful completion of biannual physical fitness testing, combative training, occupation-specific training, and periodic combat deployments.¹ In addition, participants in frequent military combative training (which also includes patients with a combat-arms designated military occupation specialty) or other analogous at-risk activity were designated as participants in “contact” or “forced overhead” types of sport. Hyperlaxity was assessed clinically by the presence of a 2+ sulcus sign in either neutral or external rotation or an asymmetrical Gagey sign.^{2,13,27} Preoperative radiographs were analyzed for glenoid bone loss by noting whether glenoid lesions on the anteroposterior radiographs were present as either avulsion fractures or loss of inferior contour. For patients who had bone loss evident on anteroposterior radiographs, we measured glenoid bone loss based on CT scans by using a ratio of defect width to the diameter of the assumed inferior circle of the glenoid.³³ We did this to confirm that all patients who underwent an arthroscopic Bankart procedure did not have critical bone loss ($\geq 20\%$) present. We also examined whether the ISI score could be used in risk assessment for additional secondary outcomes: postoperative reoperation, postoperative persistent pain, and post-instability arthropathy. Post-instability arthropathy was defined as midrange pain with range of motion with Samilson-Prieto grade II or III on radiographs.^{8,30}

Surgical procedure

Multiple surgeons at the same institution performed the arthroscopic Bankart repair, with the patients under general anesthesia in the beach-chair or lateral decubitus position, depending on surgeon preference. A 30° arthroscope was introduced through a standard posterior viewing portal, and the glenohumeral joint was inspected to verify suspected pathology. Of note, patients with humeral avulsion of the glenohumeral ligament (HAGL) lesions, a superior labral tear from anterior to posterior (SLAP), or a posterior labral repair were excluded. Dual anterior midglenoid and anterosuperior portals were established above the subscapularis tendon and anterolateral adjacent to the biceps tendon in the rotator interval, respectively. Cannulas in the anterosuperior portal, anterior portal, and posterior viewing portal were used. A posteroinferior and/or percutaneous trans-subscapularis portal was created, depending on surgeon preference, for anchor placement and/or suture shuttling. Through the anterosuperior portal, labral elevation was performed in the zone of injury, typically mobilizing from the 2- to 3-o'clock position around past the 6-o'clock position in a right shoulder; this was carried medially on the glenoid neck to allow visualization of the underlying subscapularis muscle fibers. Mobility was assessed for advancement and tensioning of the labrum and inferior glenohumeral ligamentous complex, and the anterior glenoid was prepared with a rasp and shaver to facilitate healing of the repaired capsulolabrum. A minimum of 3 suture anchors were placed (biocomposite or polyetheretherketone [DePuy Mitek, Raynham, MA, USA] or SutureTak [Arthrex, Naples, FL, USA]) below the equator. Suture passage was performed using a shuttling device (SutureLasso; Arthrex), starting approximately 1 cm off the glenoid face, with advancement of the capsulolabral tissue superiorly. This labral repair

and capsular shift were titrated depending on injury chronicity and the degree of capsular redundancy. Standard arthroscopic knot tying was performed with a sliding-knot configuration and reverse alternating half-hitches for backup fixation, with knots directed away from the glenoid surface in the capsulolabral tissue. These steps were repeated for each anchor used in the repair and capsular shift.

Postoperatively, patients were maintained in a sling at neutral rotation for 6 weeks. Passive and active-assisted range-of-motion exercises were initiated at 6 weeks postoperatively and advanced accordingly. Rotator cuff and periscapular strengthening exercises were begun at 12 weeks, and closed-chain exercises, resisted eccentric motions, and overhead throwing were integrated between 16 and 20 weeks. After final clearance at 24 weeks postoperatively, full participation in sporting activities was permitted, and the goal was to successfully pass the Army Physical Fitness Test at 6 months postoperatively.

Statistical analysis

Calculations were performed using SAS software (version 9.2; SAS Institute, Cary, NC, USA) with the assistance of a biostatistician. Continuous variables are described using means with standard deviations, and categorical variables are described using frequencies and percentages. A 2-tailed independent-samples Student *t* test was used to compare means between groups of continuous parametric data. The Fisher exact test and Pearson χ^2 test were used to compare categorical variables. A multivariate logistic regression analysis was performed to identify which variables independently affected a recurrent dislocation, and each variable was tested for independence. Significant independent predictors were determined to be those that maintained $P < .05$, with an odds ratio and 95% confidence interval exclusive of 1.0. In addition, to assess and compare the sensitivity and specificity of using the ISI framework as predictive of failure, the receiver operator characteristic (ROC) curve was plotted.

Results

A total of 131 patients were identified with a minimum of 2 years' follow-up during the study period. Preoperative patient demographic data and the presence of risk factors for recurrent instability are shown in Table II. Of all patients, 34 (26%) sustained recurrent instability after primary arthroscopic stabilization. Among these, 22 (65%) sustained a recurrent dislocation and 12 (35%) had a repeated subluxation event. Of the 34 patients, 21 (62%) were treated with revision anterior stabilization whereas 13 (38%) elected for continued nonoperative management after recurrent anterior instability (11 subluxations [8.4%] and 2 dislocations [1.5%]).

Symptomatic post-instability arthropathy occurred in 4 patients (3%) after primary arthroscopic Bankart repair, and 53 patients (41%) complained of intermittent mild to moderate postoperative pain at the time of final follow-up. The mean cumulative ISI score of patients with a failed Bankart repair was not statistically different than that of patients with a successful repair (3.41 vs 3.5, $P = .739$). On application of the ISI score to all patients and after a multivariate logistic regression analysis, no individual ISI domain was identified as an independent risk factor for subsequent surgical failure. Age

Table II Preoperative patient demographic data and presence of risk factors for recurrent instability

	Data
Sex	
Male	119 (91%)
Female	12 (9%)
Age, mean (range), yr	
At surgery	26.8 (19-47)
At first dislocation	23.9 (15-46)
Combat-arms military occupational specialty	
Yes	42 (32%)
No	89 (68%)
Age < 20 yr at surgery	
Yes	11 (8%)
No	120 (92%)
Glenoid loss	
Loss of contour	9 (7%)
No loss of contour	122 (93%)
Hill-Sachs lesion	
Visible	26 (20%)
Not visible	105 (80%)
Degree of sports participation	
Competitive	131 (100%)
Recreational or none	0 (0%)
Type of sport	
Contact or forced overhead	87 (66%)
Other	44 (34%)
Shoulder hyperlaxity	
Present	19 (15%)
Not present	112 (85%)
ISI score, mean (range)	3.5 ± 1.38 (2-8)

ISI, Instability Severity Index.

younger than 20 years at the time of surgery ($P = .134$), glenoid bone loss ($P = .314$), Hill-Sachs lesion ($P = .709$), competitive-level participation in sports ($P = .756$), participation in contact or overhead sports ($P = .056$), and shoulder hyperlaxity ($P = .546$) were all found to not independently increase the risk of recurrent dislocation. **Table III** presents a comparison of the successful Bankart repair group versus the failed Bankart repair group, and **Table IV** shows application of the independent analysis.

The presence of preoperative attritional glenoid bone loss was predictive of post-instability arthropathy (100%, $P = .008$), with all patients having midrange pain with range of motion and Samilson-Prieto grade II or III on radiographs. Involvement in contact or forced overhead activity was associated with a decreased risk of persistent pain postoperatively (33%, $P = .021$). In addition, the presence of preoperative shoulder hyperlaxity was associated with increased postoperative reoperation rates (37%, $P = .039$). **Tables V-VII** show independent analyses of individual ISI domains on selected secondary outcomes. For ROC curve analysis, the sensitivity and specificity of the ISI score as a predictive framework for failure found the area under the curve to be 0.5258 (**Fig. 1**).

Table III Comparison of successful Bankart repair group versus failed Bankart repair group

	Successful Bankart repair group (n = 97)	Failed Bankart repair group (n = 34)
Sex		
Male	91 (94%)	28 (82%)
Female	6 (6%)	6 (18%)
Laterality		
Right	52 (54%)	20 (59%)
Left	45 (46%)	14 (41%)
Combat-arms military occupational specialty		
Yes	26 (27%)	16 (47%)
No	71 (73%)	18 (53%)
Glenoid loss of contour		
Yes	8 (8%)	1 (3%)
No	89 (92%)	33 (97%)
Hill-Sachs lesion		
Yes	20 (21%)	6 (18%)
No	77 (79%)	28 (82%)
Shoulder hyperlaxity		
Yes	13 (13%)	6 (18%)
No	84 (87%)	28 (82%)
Type of sport		
Contact	37 (38%)	13 (38%)
Overhead	32 (33%)	5 (15%)
Other	28 (33%)	16 (47%)

Table IV Independent risk factors for postoperative failure

ISI score risk factor	OR	95% CI for OR	P value
Age < 20 yr at surgery	2.63	0.11-1.35	.134
Glenoid loss	0.33	0.36-24.63	.314
Hill-Sachs lesion	0.82	0.44-3.33	.709
Competitive degree of sports participation	1.81	0.01-23.29	.756
Contact or forced overhead type of sport	0.45	0.98-4.89	.056
Shoulder hyperlaxity	1.39	0.25-2.08	.546

ISI, Instability Severity Index; OR, odds ratio; CI, confidence interval. None of the individual ISI domains was found to be predictive of subsequent failure after primary arthroscopic Bankart repair.

Discussion

This study reports a 26% failure rate after arthroscopic Bankart repair in a high-risk military demographic, which is consistent with the higher end of other relevant series in the literature, particularly those with more active young patients.^{5,19,23,26-28,34,35,41} Contrary to the findings of previous validation studies, the ISI score and its individual risk factors were not predictive of subsequent failure after primary arthroscopic Bankart repair in an active-duty military population. However, we did demonstrate that individual risk factors may be predictive of

Table V Independent risk factors for postoperative reoperation

ISI score risk factor	OR	95% CI for OR	P value
Age < 20 yr at surgery	2.70	0.10-1.38	.140
Glenoid loss	0.20	0.24-102.68	.300
Hill-Sachs lesion	1.01	0.33-2.94	.983
Competitive degree of sports participation	1.21	0.02-34.64	.917
Contact or forced overhead type of sport	0.88	0.46-2.84	.777
Shoulder hyperlaxity	3.03	0.11-0.95	.039*

ISI, Instability Severity Index; OR, odds ratio; CI, confidence interval.

* Shoulder hyperlaxity was associated with increased postoperative reoperation rates ($P = .039$).

Table VI Independent risk factors for postoperative persistent pain

ISI score risk factor	OR	95% CI for OR	P value
Age < 20 yr at surgery	1.85	0.16-1.86	.326
Glenoid loss	1.93	0.13-2.03	.346
Hill-Sachs lesion	1.10	0.38-2.17	.830
Competitive degree of sports participation	0.68	0.09-24.21	.783
Contact or forced overhead type of sport	0.42	1.14-5.04	.021*
Shoulder hyperlaxity	1.38	0.27-1.91	.508

ISI, Instability Severity Index; OR, odds ratio; CI, confidence interval.

* Statistically significant.

Table VII Independent risk factors for post-instability arthropathy

ISI score risk factor	OR	95% CI for OR	P value
Age < 20 yr at surgery	1.12	0.04-19.81	.940
Glenoid loss	17.14	0.01-0.48	.008*
Hill-Sachs lesion	4.35	0.03-1.74	.155
Competitive degree of sports participation	0.18	0.12-258.68	.380
Contact or forced overhead type of sport	0.16	0.64-62.36	.116
Shoulder hyperlaxity	2.00	0.05-5.03	.552

ISI, Instability Severity Index; OR, odds ratio; CI, confidence interval.

* Glenoid bone loss was found to be an independent risk factor for post-instability arthropathy ($P = .008$).

persistent morbidity and the development of post-instability arthropathy, both of which have been under-evaluated endpoints with instability surgery.¹¹ Risk factors for the development of post-instability arthropathy include age greater than 25 years at the time of initial dislocation, high-energy mechanism of injury, and history of alcohol abuse.^{21,37} In a cohort of 227 patients, Hovelius and Saeboe²¹ found that post-instability arthropathy developed after a primary shoulder dislocation in 66% of patients.³⁷ The same researchers also

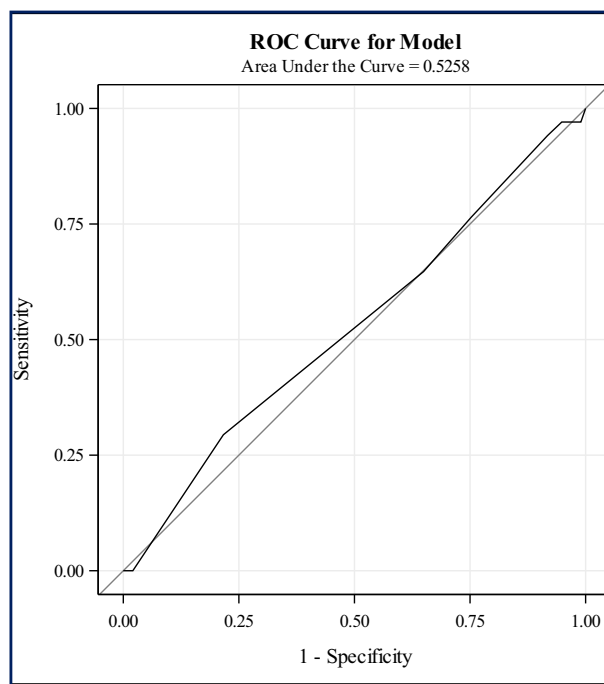


Figure 1 Receiver operator characteristic (ROC) curve analysis for Instability Severity Index score. The cumulative Instability Severity Index score was a poor predictor of failure of arthroscopic stabilization on ROC curve analysis.

concluded that among those patients requiring stabilization surgery, approximately two-thirds of patients younger than 25 years had some form of arthropathy at final follow-up.^{20,37} Post-instability arthropathy may be an important predictor of secondary osteoarthritis or may be a proxy risk factor that reflects a more prolonged course of recurrent shoulder instability.³⁷

Previous validation studies of the ISI score have calculated thresholds for failure rates. Rouleau et al²⁸ established that the ISI score threshold for considering open surgery was 4.8, which was lower than the threshold of 6 originally described by Balg and Boileau.² In a study of 141 patients from the United Kingdom, Phadnis et al²⁷ suggested that an ISI score of less than 4 was safe, with only a 4% risk of failure versus 70% for an ISI score of 4 or greater. Additionally, Thomazeau et al³⁴ performed a multicenter study with 125 patients and showed acceptable results with an ISI score threshold of less than 4 at 3-year follow-up. In our study, we were unable to posit a suggested threshold for failure, as the cumulative ISI score was a poor predictor of failure of arthroscopic stabilization on ROC curve analysis.

Although not a predictor of instability recurrence, shoulder hyperlaxity was identified as an independent risk factor for revision stabilization in our series. This finding supports previous investigations showing that patients with hyperlaxity experience redislocation and instability rates up to 30%.^{6,14} Shoulder laxity has been variably defined in existing studies, with some examiners associating this with increased anterior-posterior transition; extreme external rotation in adduction;

inferior distraction, with sulcus testing; or evidence of passive hyperabduction.^{6,13,14} Because of the retrospective nature of this study, we were unable to standardize how providers described hyperlaxity. For our study, hyperlaxity was assessed clinically by the presence of a 2+ sulcus sign in either neutral or external rotation or asymmetrical Gagey sign. This may have led to decreased sensitivity for detecting hyperlaxity in our study. Constitutional or localized shoulder laxity can be problematic for surgeons to address, as these patients have a wide range of clinical presentations and are susceptible to having higher rates of failure and instability after surgical repair.^{6,14} In certain circumstances, shoulder laxity may contribute to symptomatic multidirectional instability, although we did exclude patients with multidirectional instability from this study. Previous studies have indicated that approximately 30% of patients with multidirectional laxity present with an anterior traumatic dislocation.^{6,14} In these patients with hyperlaxity and anterior shoulder instability, increased capsular volume reduction and/or posterior anchor augmentation may be needed to create a balanced retensioning of the inferior glenohumeral ligament complex.

An additional physical examination finding that has proved useful in evaluating patients with anterior instability is the apprehension test. Safran et al²⁹ used the apprehension test to determine the risk of recurrent dislocation in young patients 6 weeks after their initial anterior shoulder dislocation. At 2 years' follow-up, recurrent dislocations occurred in 36.8% and 71.4% of those with negative and positive 6-week apprehension signs, respectively. Safran et al found that the apprehension test can categorize patients into high- and low-risk groups after the initial shoulder dislocation. This may be a helpful tool that can be included as a risk factor tool to determine patients at higher risk of recurrence. Patients at high risk of recurrent shoulder dislocation after arthroscopic Bankart repair have several other surgical options, such as the modified Bristow-Latarjet coracoid transfer, open Bankart repair, and/or adjunctive remplissage. The Latarjet procedure has been documented to significantly lower the redislocation rate in numerous studies, with most reports indicating a recurrence rate of less than 5%.^{4,9,15,22} However, this may be offset by the potential for significant complications in up to 25%-30% of patients,^{2,31,36,39} including neurovascular injury, premature arthritis, nonunion or graft resorption, and hardware complications.^{4,9,15,22} The modern open Bankart repair techniques involving suture and anchor fixation and capsular plication have shown little difference in redislocation rates compared with contemporary arthroscopic repairs,^{10,18} but they have many disadvantages over arthroscopic repairs, such as being more invasive techniques and yielding increased surgical-site morbidity (eg, scarring or subscapularis dysfunction), higher blood loss, and potentially, limitations in range of motion.^{2,3,10,27,32} Furthermore, patient preferences often favor arthroscopic repairs, likely because of minimal scarring involved with arthroscopic repairs.³²

Some limitations are associated with beach-chair positioning for the treatment of instability. At our institution,

patients were treated in either the beach-chair or lateral decubitus position depending on surgeon preference. The lateral decubitus position allows the surgeon to have abundant exposure to all aspects of the glenohumeral joint, which is helpful in instability cases in which extensive visualization of the inferior aspect of the joint is required.¹⁷ Although excellent clinical outcomes can be obtained with either beach-chair or lateral decubitus positioning, lower recurrence rates have been shown with patients in the lateral decubitus position.¹² As with any retrospective military investigation, this study has several limitations that must be acknowledged. In adapting the ISI domains, it remains difficult to extrapolate levels of sporting participation to a military context, particularly those identified as competitive. Subsequent validation studies have also had difficulty defining the level of sporting participation because most "recreational" athletes are often still periodically involved in competitive sporting participation.^{2,27,28,34} Given the rigorous physical profile and occupational demands of military service members relative to their civilian counterparts, the level of sporting involvement was extrapolated as competitive for all patients. As a result, this may have artificially inflated the generated ISI score across all patients, irrespective of failure endpoints. Conversely, the military population has unique and rigorous physical requirements that may not be universally applicable to the general population or selected athletic cohorts.

Owing to the retrospective nature of this study, not all preoperative anteroposterior radiographs were taken in internal rotation, as conducted in the original study.² Accordingly, this may have led to a diminished sensitivity for detection of Hill-Sachs lesions in certain cases. In addition, using anteroposterior radiographs to quantify bone loss has not proved to be sufficient because it can be difficult for surgeons to measure the area of glenoid bone loss.³³ Advanced imaging may also be used as an adjunct to plain radiographs in the preoperative period, which would allow for further characterization and measurement of both humeral and glenoid bone loss. Di Giacomo et al⁷ introduced an advanced imaging technique—the on-track–off-track method—that used CT with 3-dimensional reconstruction to evaluate Hill-Sachs lesions and glenoid bone loss at the same time. They developed a treatment algorithm based on quantification of bone loss.⁷ Gyftopoulos et al¹⁶ further advanced the on-track–off-track method with magnetic resonance imaging evaluation of Hill-Sachs lesions and glenoid bone loss. They found that this method was 84.2% accurate in determining engaging lesions that are inherently unstable. There may be value in adding preoperative advanced imaging findings to the ISI score or other predictive indices for instability recurrence. We did not measure or control for subcritical levels of glenoid bone loss (ie, <20%), the presence of off-track lesions, and/or the degree of engaging defects in our study. Despite these limitations, this study represents one of the larger studies to evaluate the ISI score in a high-risk cohort of patients.

Conclusion

Performing anterior shoulder stabilization surgery with an arthroscopic Bankart procedure can result in a higher recurrence rate in certain at-risk populations. Our results show that the composite ISI score and individual domains failed to predict a heightened risk of instability recurrence after primary arthroscopic Bankart repair in a military population. However, we did demonstrate that the presence of subcritical anterior glenoid bone loss heralded the onset of early post-instability arthropathy and that shoulder hyperlaxity predicted an increased risk of revision stabilization but not instability recurrence. Further research is warranted to better differentiate high-risk patients who may be more effectively treated with more aggressive methods of anterior shoulder stabilization, such as an open repair or Bristow-Latarjet procedure.

Disclaimer

Brian R. Waterman has received royalties and consultant payments from Vericel (speakers bureau), which is not related to the subject of this article. All the other authors, their immediate families, and any research foundations with which they are affiliated have not received any financial payments or other benefits from any commercial entity related to the subject of this article.

References

1. Army Regulation 40-501. Standards of medical fitness. Washington, DC: Department of the Army; 2007.
2. Balg F, Boileau P. The instability severity index score: a simple preoperative score to select patients for arthroscopic or open shoulder stabilisation. *J Bone Joint Surg Br* 2007;89:1470-7. <http://dx.doi.org/10.1302/0301-620X.89B11.18962>
3. Boileau P, Villalba M, Hery J, Balg F, Ahrens P, Neyton L. Risk factors for recurrence of shoulder instability after arthroscopic Bankart repair. *J Bone Joint Surg Am* 2006;88:1755-63. <http://dx.doi.org/10.2106/JBJS.E.00817>
4. Burkhart S, DeBeer J, Barth J. Results of modified Latarjet reconstruction in patients with anteroinferior instability and significant bone loss. *Arthroscopy* 2007;23:1033-41. <http://dx.doi.org/10.1016/j.arthro.2007.08.009>
5. Calvo E, Granizo J, Fernandez-Yruegas D. Criteria for arthroscopic treatment of anterior instability of the shoulder a prospective study. *J Bone Joint Surg Br* 2005;87:677-83. <http://dx.doi.org/10.1302/0301-620X.87B5.15794>
6. Chechik O, Maman E, Dolkart O, Khashan M, Shabtai L, Mozes G. Arthroscopic rotator interval closure in shoulder instability repair: a retrospective study. *J Shoulder Elbow Surg* 2010;19:1056-62. <http://dx.doi.org/10.1016/j.jse.2010.03.001>
7. Di Giacomo G, Itoi E, Burkhart S. Evolving concept of bipolar bone loss and the Hill-Sachs lesion: from "engaging/non-engaging" lesion to "on-track/off-track" lesion. *Arthroscopy* 2014;30:90-8. <http://dx.doi.org/10.1016/j.arthro.2013.10.004>
8. Elsharkawi M, Cakir B, Reichel H, Kappe T. Reliability of radiologic glenohumeral osteoarthritis classifications. *J Shoulder Elbow Surg* 2013;22:1063-7. <http://dx.doi.org/10.1016/j.jse.2012.11.007>
9. Emami M, Solooki S, Meshksari Z, Vosoughi A. The effect of open Bristow-Latarjet procedure for anterior shoulder instability: a 10-year study. *Musculoskelet Surg* 2011;95:231-5. <http://dx.doi.org/10.1007/s12306-011-0149-0>
10. Fabbriani C, Milano G, Demontis A, Fadda S, Ziranu F, Mulas P. Arthroscopic versus open treatment of Bankart lesion of the shoulder: a prospective randomized study. *Arthroscopy* 2004;20:456-62. <http://dx.doi.org/10.1016/j.arthro.2004.03.001>
11. Franceschi F, Papalia R, Buono AD, Vasta S, Maffuli N, Denaro V. Glenohumeral osteoarthritis after arthroscopic Bankart repair for anterior instability. *Am J Sports Med* 2011;39:1653-9. <http://dx.doi.org/10.1177/0363546511404207>
12. Frank R, Saccomanno M, McDonald L, Moric M, Romeo A, Provencher M. Outcomes of arthroscopic anterior shoulder instability in the beach chair versus lateral decubitus position: a systematic review and meta-regression analysis. *Arthroscopy* 2014;30:1349-65. <http://dx.doi.org/10.1016/j.arthro.2014.05.008>
13. Gagey O, Gagey N. The hyperabduction test: an assessment of the laxity of the inferior glenohumeral ligament. *J Bone Joint Surg Br* 2000;82:69-74.
14. Gerber C, Nyffeler R. Classification of glenohumeral joint instability. *Clin Orthop Relat Res* 2002;400:65-76. <http://dx.doi.org/10.1097/00003086200207000-00009>
15. Griesser MJ, Harris JD, McCoy BW, Hussain WM, Jones MH, Bishop JY, et al. Complications and reoperations after Bristow-Latarjet shoulder stabilization: a systematic review. *J Shoulder Elbow Surg* 2013;22:286-92. <http://dx.doi.org/10.1016/j.jse.2012.09.009>
16. Gyftopoulos S, Beltran L, Bookman J, Rokito A. MRI evaluation of bipolar bone loss using on-track off-track method: a feasibility study. *AJR Am J Roentgenol* 2015;205:848-52. <http://dx.doi.org/10.2214/AJR.14.14266>
17. Hamamoto J, Frank R, Higgins J, Provencher M, Romeo A, Verma N. Shoulder arthroscopy in the lateral decubitus position. *Arthrosc Tech* 2017;6:1169-75. <http://dx.doi.org/10.1016/j.eats.2017.04.004>
18. Harris J, Gupta A, Mall N. Long-term outcomes after Bankart shoulder stabilization. *Arthroscopy* 2013;29:920-33. <http://dx.doi.org/10.1016/j.arthro.2012.11.010>
19. Hobby J, Griffin D, Dunbar M, Boileau P. Is arthroscopic surgery for stabilisation of chronic shoulder instability as effective as open surgery? A systematic review and meta-analysis of 62 studies including 3044 arthroscopic operations. *J Bone Joint Surg Br* 2007;89:1188-96. <http://dx.doi.org/10.1302/0301-620X.89B9.18467>
20. Hovelius L, Rahme H. Primary anterior dislocation of the shoulder: long-term prognosis at the age of 40 years or younger. *Knee Surg Sports Traumatol Arthrosc* 2016;24:330-42. <http://dx.doi.org/10.1007/s00167-015-3980-2>
21. Hovelius L, Saeboe M. Neer Award 2008: Arthropathy after primary anterior shoulder dislocation—223 shoulders prospectively followed up for twenty-five years. *J Shoulder Elbow Surg* 2008;18:339-47. <http://dx.doi.org/10.1016/j.jse.2008.11.004>
22. Hovelius L, Vikerfors O, Olofsson A, Svensson O, Rahme H. Bristow-Latarjet and Bankart: a comparative study of shoulder stabilization in 185 shoulders during a seventeen-year follow-up. *J Shoulder Elbow Surg* 2011;20:1095-101. <http://dx.doi.org/10.1016/j.jse.2011.02.005>
23. Kim S, Ha K, Cho Y, Ryu B, Oh I. Arthroscopic anterior stabilization of the shoulder: two to six-year follow-up. *J Bone Joint Surg Am* 2003;85:1511-8. <http://dx.doi.org/10.2106/00004623-200308000-00012>
24. Olds M, Ellis R, Donaldson K, Parmar P, Kersten P. Risk factors which predispose first-time traumatic anterior shoulder dislocations to recurrent instability in adults: a systematic review and meta-analysis. *Br J Sports Med* 2015;49:913-23. <http://dx.doi.org/10.1136/bjsports-2014-094342>
25. Owens B, Dawson L, Burks R, Cameron K. Incidence of shoulder dislocation in the United States military: demographic considerations

- from a high-risk population. *J Bone Joint Surg Am* 2009;91:791-6. <http://dx.doi.org/10.2106/JBJS.H.00514>
26. Owens B, Harrast J, Hurwitz S, Thompson T, Wolf J. Surgical trends in Bankart repair: an analysis of data from the American board of orthopaedic surgery certification examination. *Am J Sports Med* 2011;39:1865-9. <http://dx.doi.org/10.1177/0363546511406869>
 27. Phadnis J, Arnold C, Elmorsy A, Flannery M. Utility of the Instability Severity Index score in predicting failure after arthroscopic anterior stabilization of the shoulder. *Am J Sports Med* 2015;43:1983-8. <http://dx.doi.org/10.1177/0363546515587083>
 28. Rouleau D, Hebert-Davies J, Djahangiri A, Godbout V, Pelet S, Balg F. Validation of the instability shoulder index score in a multicenter reliability study in 114 consecutive cases. *Am J Sports Med* 2013;41:278-82. <http://dx.doi.org/10.1177/0363546512470815>
 29. Safran O, Milgrom C, Radeva-Petrova D, Jaber S, Firestone A. Accuracy of the anterior apprehension test as a predictor of risk for redislocation after a first traumatic shoulder dislocation. *Am J Sports Med* 2010;38:972-5. <http://dx.doi.org/10.1177/0363546509357610>
 30. Samilson R, Prieto V. Dislocation arthropathy of the shoulder. *J Bone Joint Surg Am* 1983;65:456-60.
 31. Shah A, Butler R, Romanowski J, Goel D, Karadagli D, Warner J. Short-term complications of the Latarjet procedure. *J Bone Joint Surg Am* 2012;94:495-501. <http://dx.doi.org/10.2106/JBJS.J.01830>
 32. Sperling J, Smith A, Cofield R, Barnes S. Patient perceptions of open and arthroscopic shoulder surgery. *Arthroscopy* 2007;23:361-6. <http://dx.doi.org/10.1016/j.arthro.2006.12.006>
 33. Sugaya H. Techniques to evaluate glenoid bone loss. *Curr Rev Musculoskelet Med* 2014;7:1-5. <http://dx.doi.org/10.1007/s12178-013-9198-3>
 34. Thomazeau H, Courage O, Barth J, Pelegri C, Charousset C, Lespagnol F, et al. Can we improve the indication for Bankart arthroscopic repair? A preliminary clinical study using the ISIS score. *Orthop Traumatol Surg Res* 2010;96:S77-83. <http://dx.doi.org/10.1016/j.otsr.2010.09.007>
 35. van der Linde JA, van Kampen DA, Terwee C, Dijksman L, Kleinjan G, Willems W. Long-term results after arthroscopic shoulder stabilization using suture anchors: an 8- to 10-year follow-up. *Am J Sports Med* 2011;39:2396-403. <http://dx.doi.org/10.1177/0363546511415657>
 36. Waterman B, Chandler P, Teague E, Provencher M, Tokish J, Pallis M. Short-term outcomes of glenoid bone block augmentation for complex anterior shoulder instability in a high-risk population. *Arthroscopy* 2016;32:1784-90. <http://dx.doi.org/10.1016/j.arthro.2016.01.051>
 37. Waterman B, Kilcoyne K, Parada S, Eichinger J. Prevention and management of post-instability glenohumeral arthropathy. *World J Orthop* 2017;8:229-41. <http://dx.doi.org/10.5312/wjo.v8.i3.000>
 38. Wilk K, Macrina L, Reinold M. Non-operative rehabilitation for traumatic and atraumatic glenohumeral instability. *N Am J Sports Phys Ther* 2006;1:16-31. <http://dx.doi.org/10.1016/j.csm.2013.07.017>
 39. Yang J, Mazzocca A, Cote M, Edgar C, Arciero R. Recurrent anterior shoulder instability with combined bone loss: treatment and results with the modified Latarjet procedure. *Am J Sports Med* 2016;44:922-32. <http://dx.doi.org/10.1177/0363546515623929>
 40. Zacchilli M, Owens B. Epidemiology of shoulder dislocations presenting to emergency departments in the United States. *J Bone Joint Surg Am* 2010;92:542-9. <http://dx.doi.org/10.2106/JBJS.I.00450>
 41. Zhang A, Montgomery S, Ngo S, Hame S, Wang J, Gamradt S. Arthroscopic versus open shoulder stabilization: current practice patterns in the United States. *Arthroscopy* 2014;30:436-43. <http://dx.doi.org/10.1016/j.arthro.2013.12.013>